

Harvard-MIT Division of Health Sciences and Technology
HST.535: Principles and Practice of Tissue Engineering
Instructor: Yuxing

BONE REGENERATION

Yuxing M.D PH.D

*Biomaterials Laboratory, Department of
Materials Science & Engineering, Tsinghua
University*

*Orthopaedic center, Dongzhimen Hospital,
Beijing University of Chinese Medicine*

Over the course of the century, orthopaedic surgeons have used many synthetic materials (metals, ceramics, polymers, and plastics, etc) to replace human tissue and provide improved function.

Bone is the basic orthopaedic biomaterial, including host bone, allograft bone, xenograft bone, and bone graft substitutes.

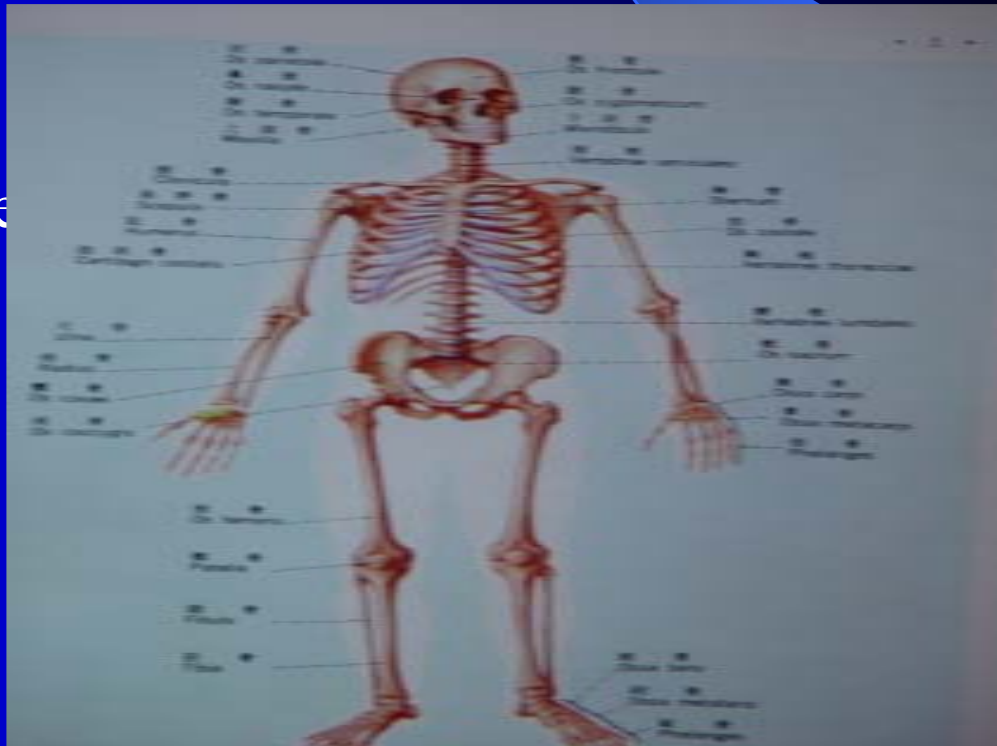
summary

- Basic knowledge of bone
- A new bone material ---nano-HA/
Collagen/PLA composite
- Clinical application of nHAC/PLA

Basic knowledge of bone

Function of bones

- Bone is a specialized connective tissue and have three major functions: to serve as (1)mechanical support, (2)sites of muscle insertion, and (3) a reserve of calcium and phosphate for organism.
- The supporting function of bone resembles a composite building system.
there are short and long tubular bones, irregular bones, flat bones and bones of a highly specific form.



Function of bones

- The skeleton is both a structural support and a metabolic organ. It serves especially for the storage of calcium and phosphate, ensuring the equilibrium of these ions in the blood serum.
- A constant level of the blood calcium is essential for life and bone plays a decisive role in maintaining this level.

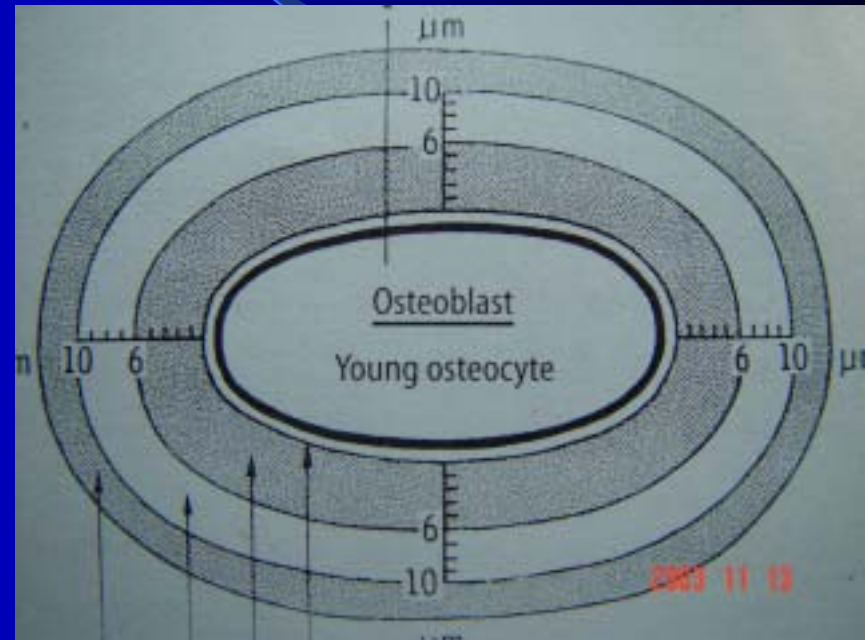
structure of bone

- The bone consists of bone matrix and bone cells.
- The bone matrix consists of 77% inorganic and 23% organic material.

The organic bone matrix—the osteoid —is 89% collagen and 5% protein, and is the site of bone mineral deposition.

structure of bone

- Osteoid is produced by large polyhedral osteoblast.
- Daily deposition of 1 μ m osteoid(=collagen)
- Total width of osteoid seam: 6 μ m
- Zone of provisional calcification: 4 μ m
- Fully calcified organic matrix(10 μ m distant from cell wall)



structure of bone

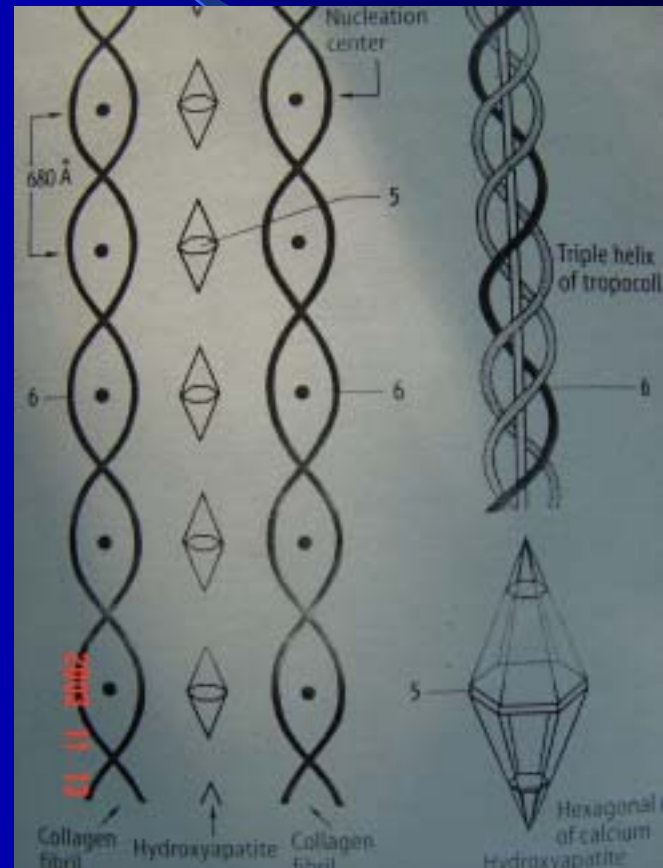
- The bone consists of bone matrix and bone cells.
- The bone matrix consists of 77% inorganic and 23% organic material.

The inorganic component of the bone tissue consists of 90% calcium phosphate and 10% calcium carbonate.

the most important mineral, calcium, is deposited in the organic matrix as **hydroxyapatite crystals**.

structure of bone

- The crystals are hexagonal and embedded alongside the collagen fibrils intervals of 68 nm.



structure of bone

- The bone consists of bone matrix and bone cells.
- All mature bone cells are derived from the preosteoblasts, which are derived from undifferentiated mesenchyme cells.
- Preosteoblasts mature to form osteoblasts, which are the true builders of bone. They produce collagen and regulate the mineralization of matrix.
- The origin of osteoclasts has not been fully established. Osteoclasts play an important part in bone resorption.

structure of bone

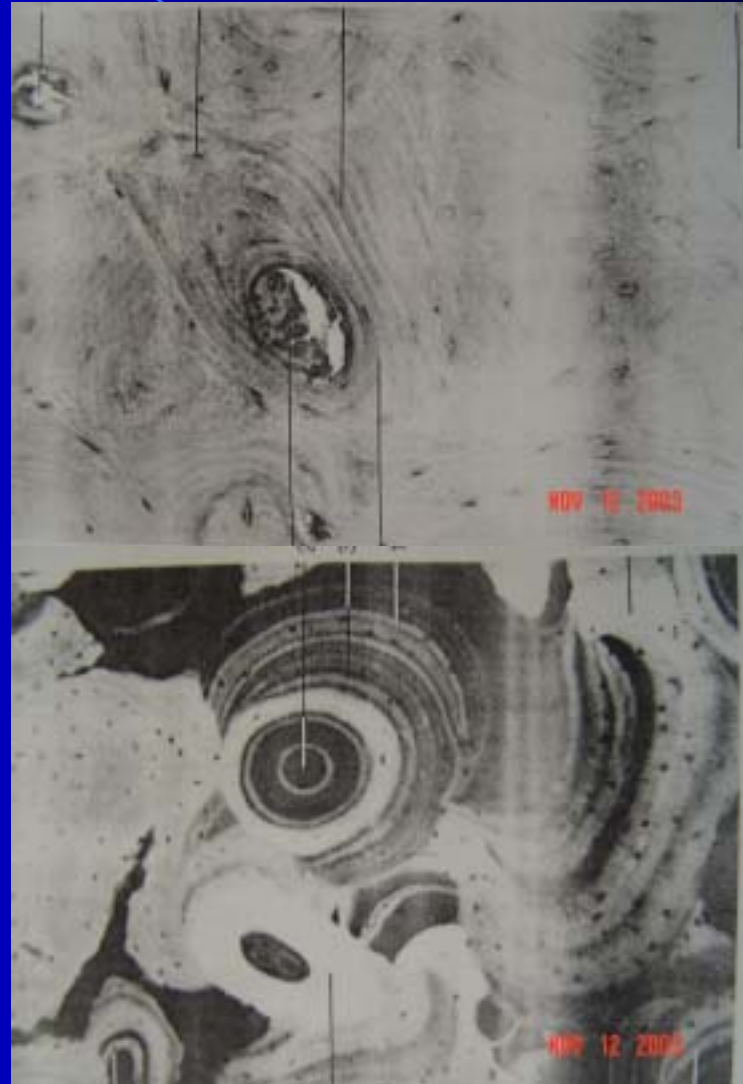
- Bone is remodeled throughout life by the activation-resorption-formation(ARF) sequence by which the coordinated actions of osteoclasts and osteoblasts replace old with new bone.

structure of bone

- Bone can be divided into two types: cortex and spongiosa.

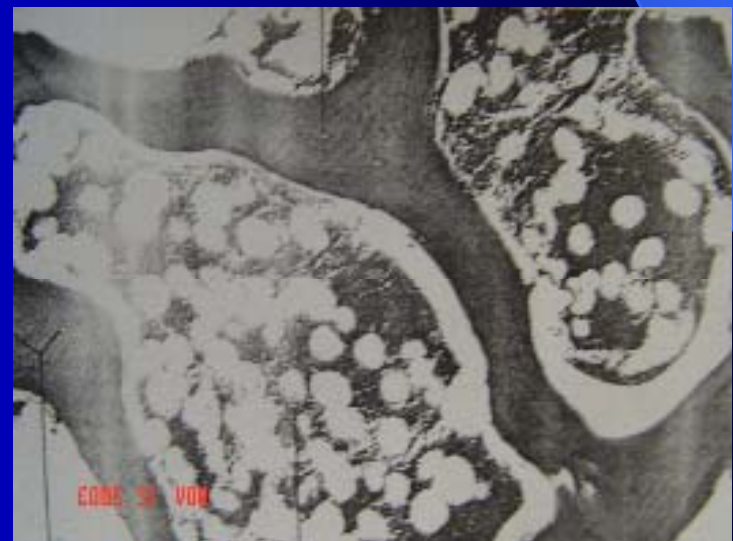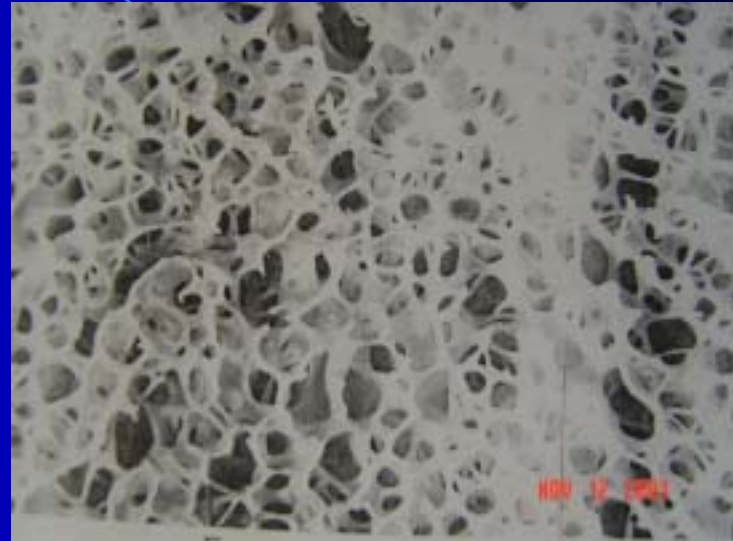
structure of bone

- Cortical bone is homogeneous and very densely structured. The typical lamellar structure of the bone is apparent in the onion-like arrangement of the osteons.



structure of bone

- A maceration specimen of the cancellous scaffolding of a vertebral body.
- The bony trabeculae constitute a honeycomb formation.
- Between the bony elements, space contain the bone marrow.

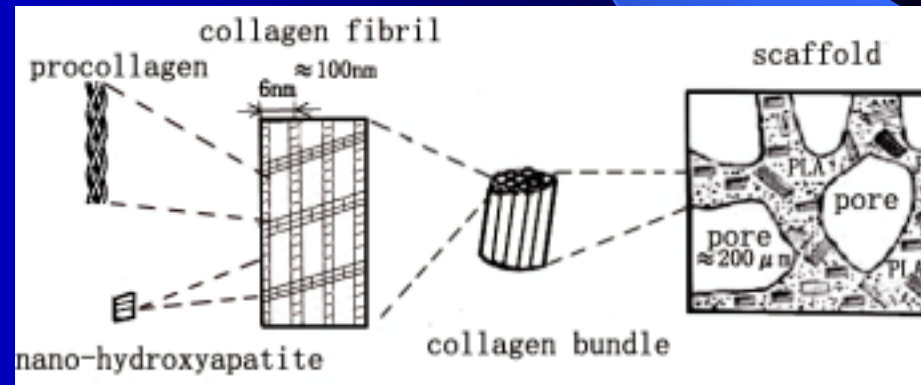
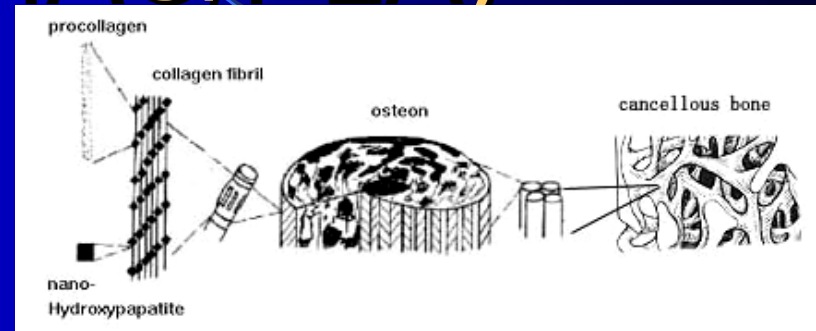


A bone scaffold material and relative research

nano-HA/ Collagen/PLA composite



nano-HA/collagen/poly(lactic acid) (nHAC/PLA)

- The bone scaffold material was developed by biomimetic synthesis .
- In main composition and hierarchical microstructure, the bone material is similar to natural bone.




nHAC/PLA

- The three dimensional porous scaffold materials mimic the microstructure of cancellous bone.
- Tests of cell culture and animal model showed that the composite material is bioactive.

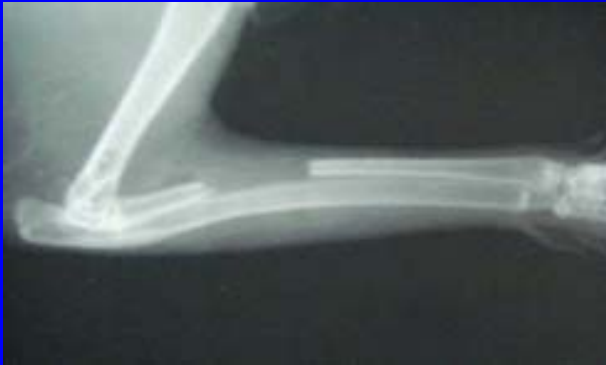

SEM of co-culture

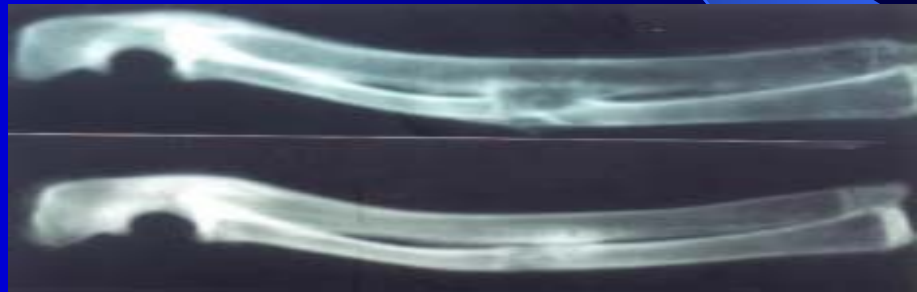
- The osteoblasts were separated from the neonatal rat calvaria and seeded into material at a concentration of 5×10^5 cells/cm².
- Osteoblasts adhered, spread and proliferate throughout the pore of the scaffold material within a week.



15 mm segmental defect model in the radius of rabbit

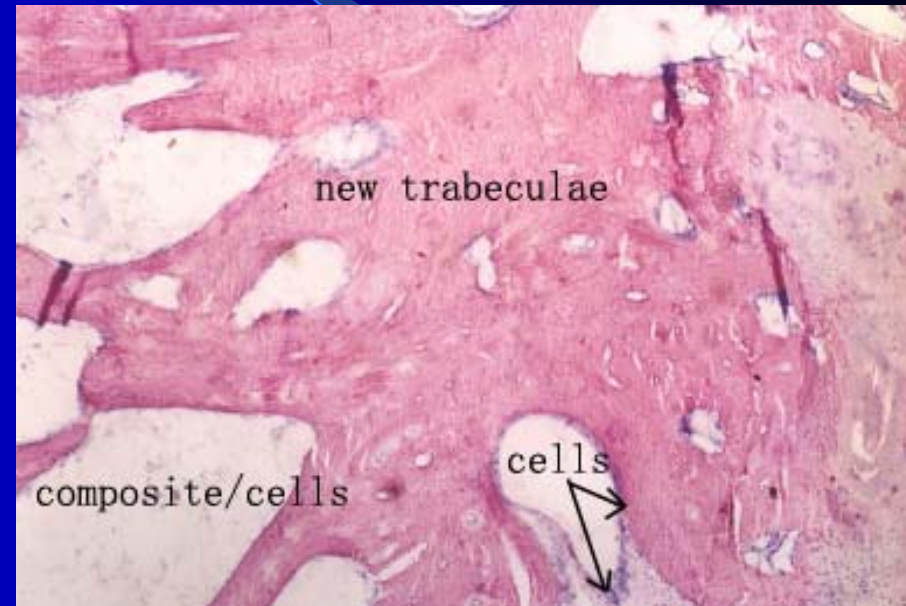
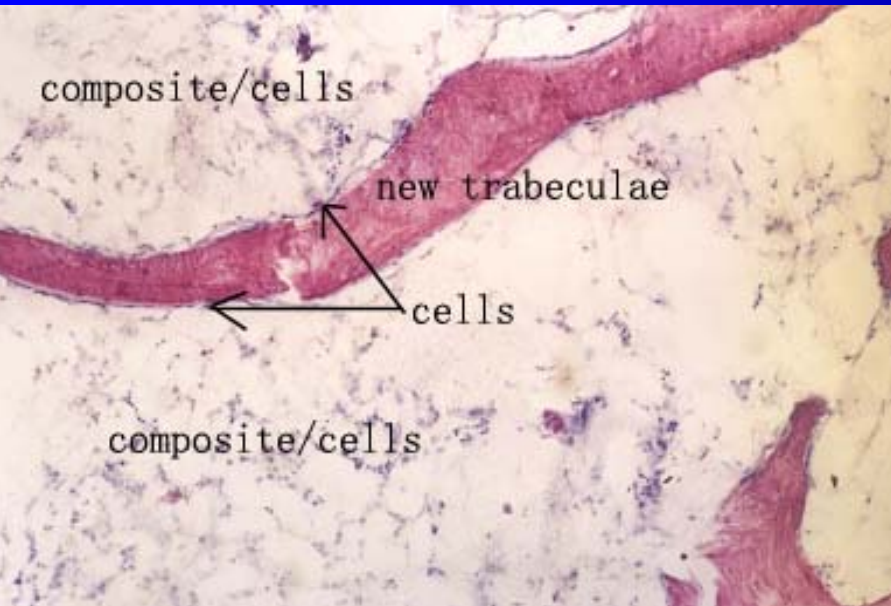


15mm nHAC/PLA
implanted, After surgery



Implant 12 weeks
new bone grow up,
cortical bone connected completely

Histology of the new bone tissue

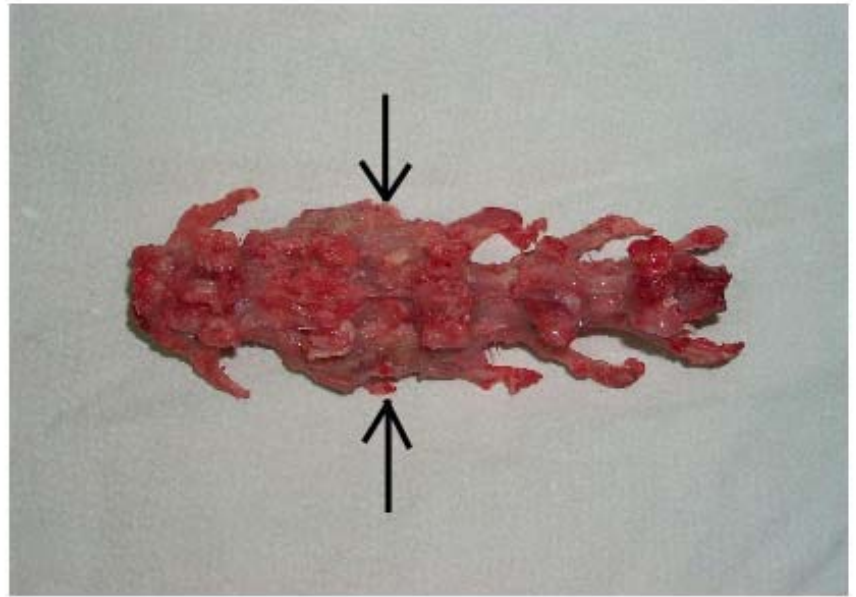
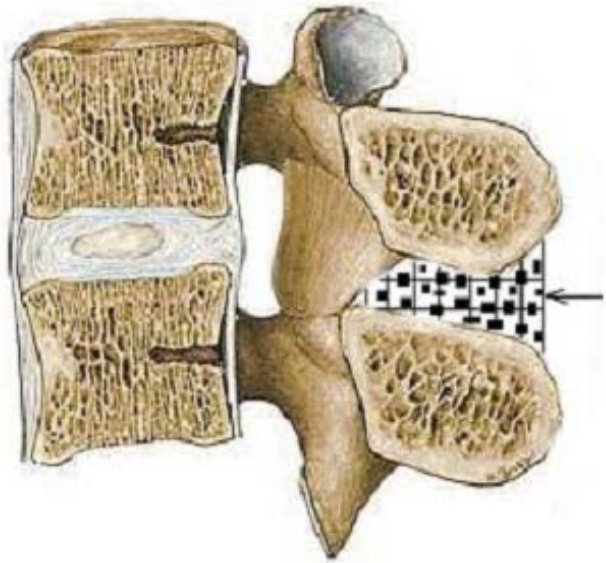


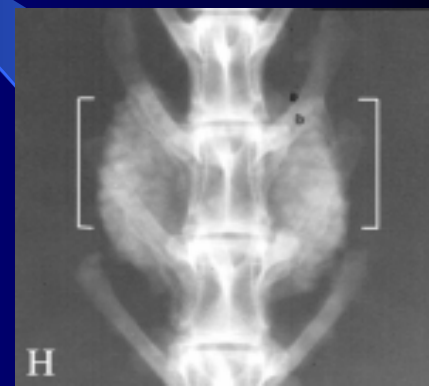
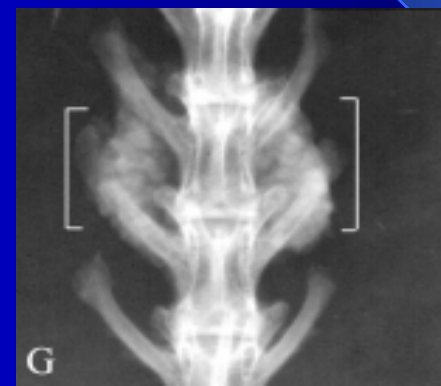
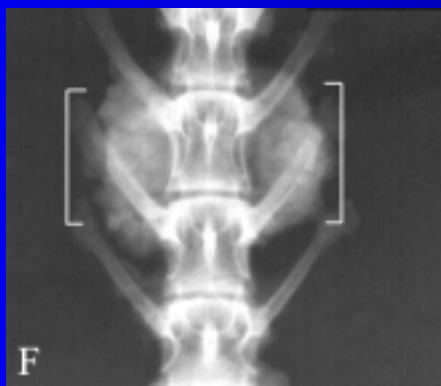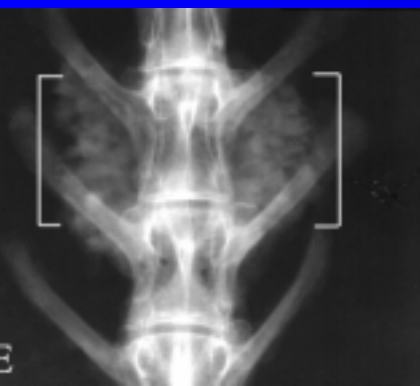
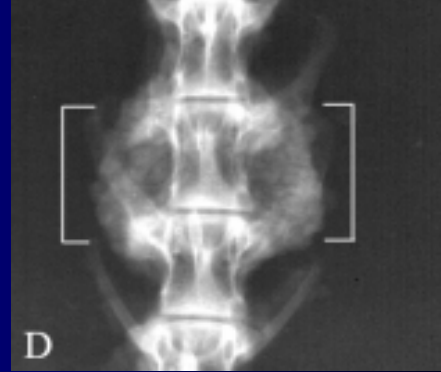
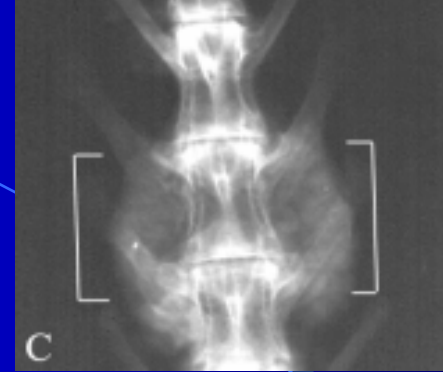
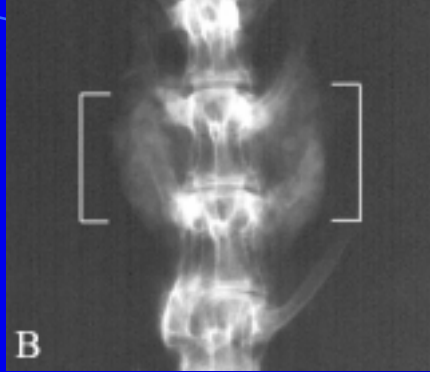
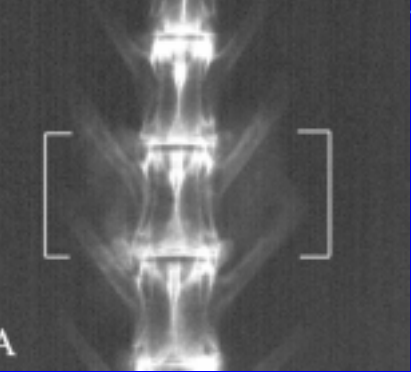
8 weeks

12 weeks

There are some islands osteoid, which was regularly lined by many cuboidal osteoblasts, indicating bone-forming activity. (HE stain)

Lumbar Spinal fusion with nHAC/PLA and rhBMP-2 in a rabbit model





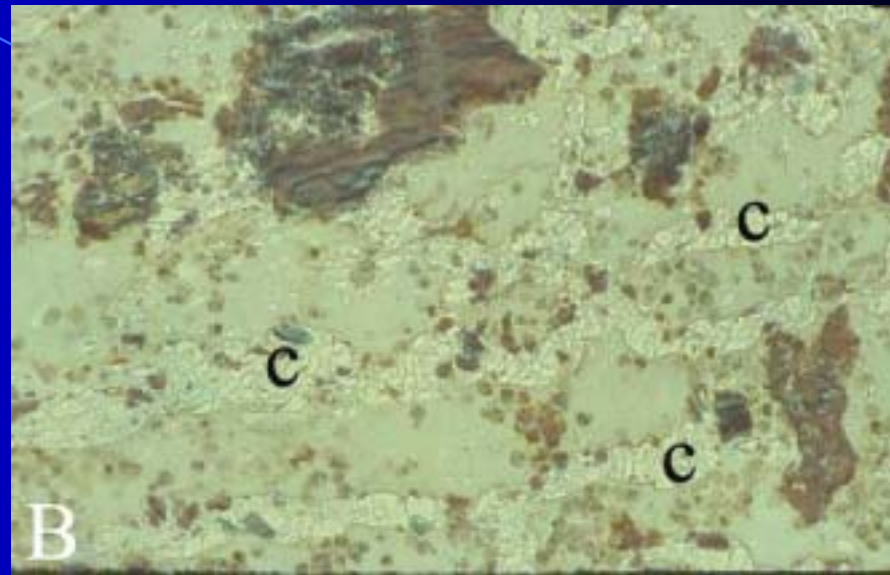
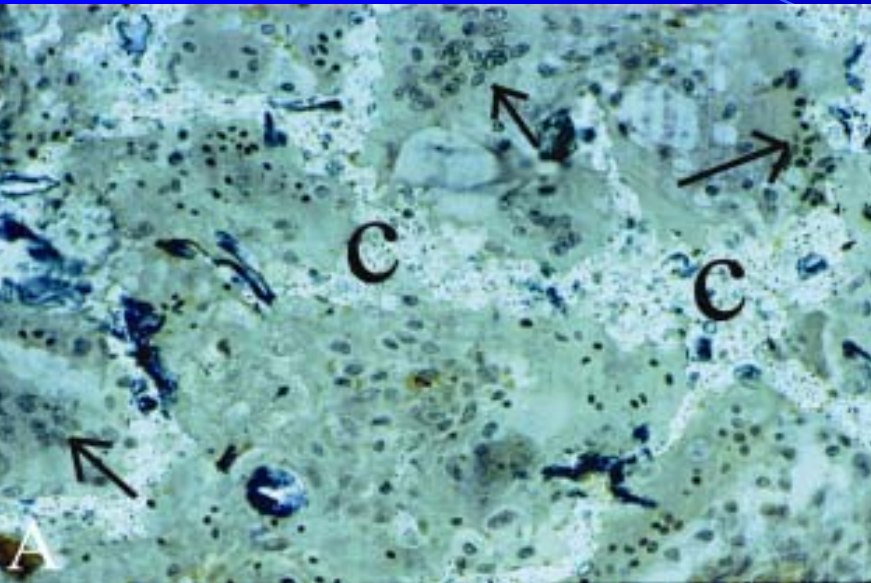
X-ray radiographs in Group nHAC/PLA and nHAC/PLA+rhBMP-2

2 weeks

4 weeks

6 weeks

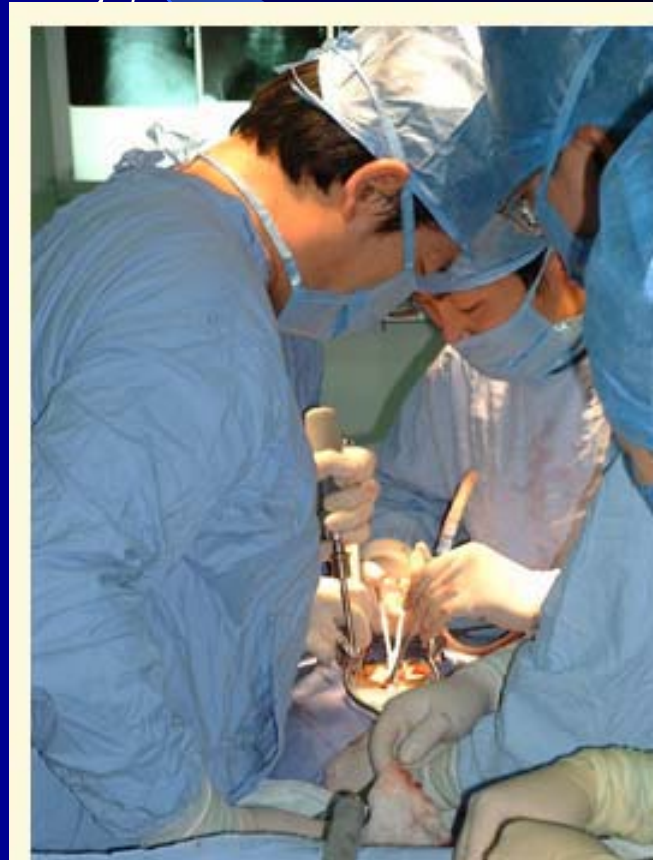10 weeks

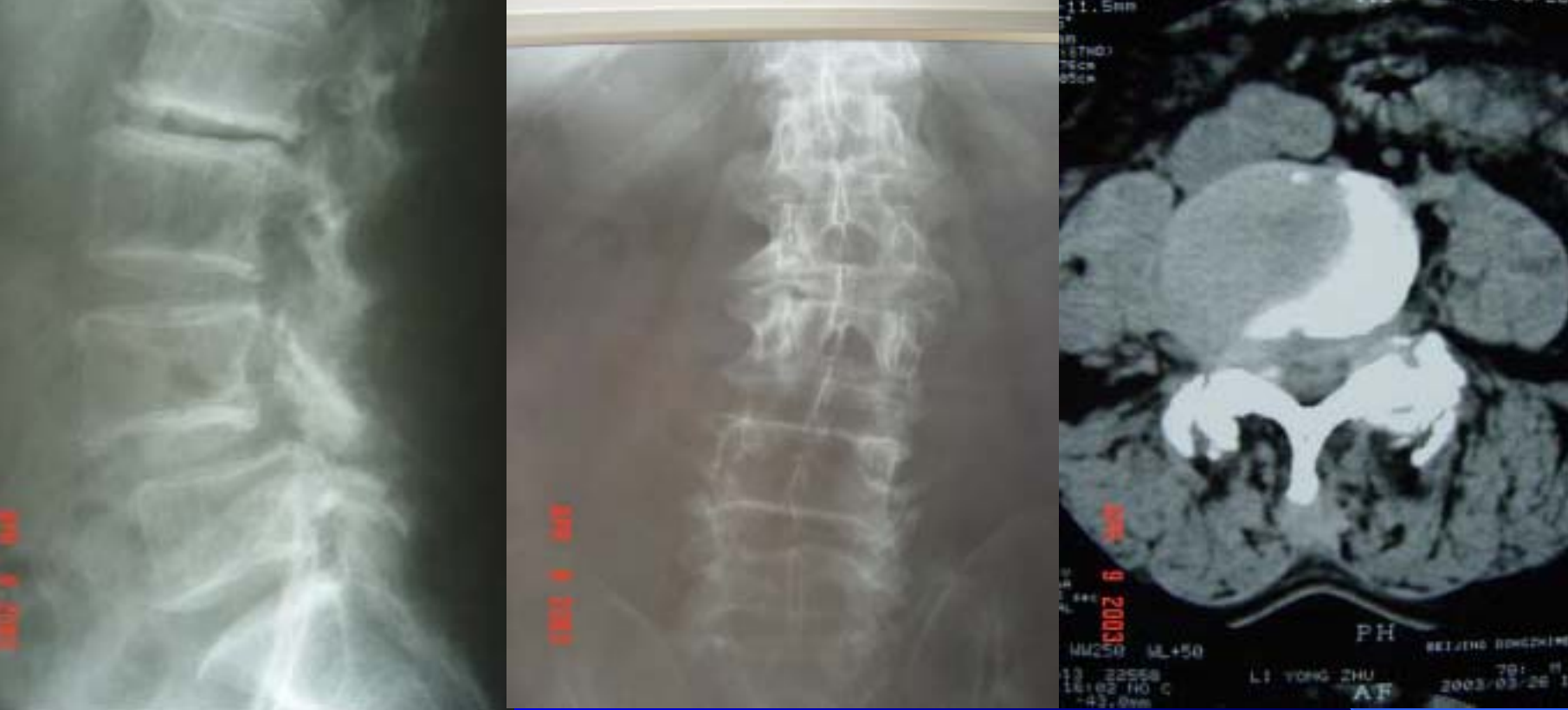

the new trabecular bone distribute in the whole fusion mass area

Clinical application of nHAC/PLA

- The clinical study began on January 15, 2003. Since then, we have completed 50 cases in orthopedic center, dongzhimen Hospital.

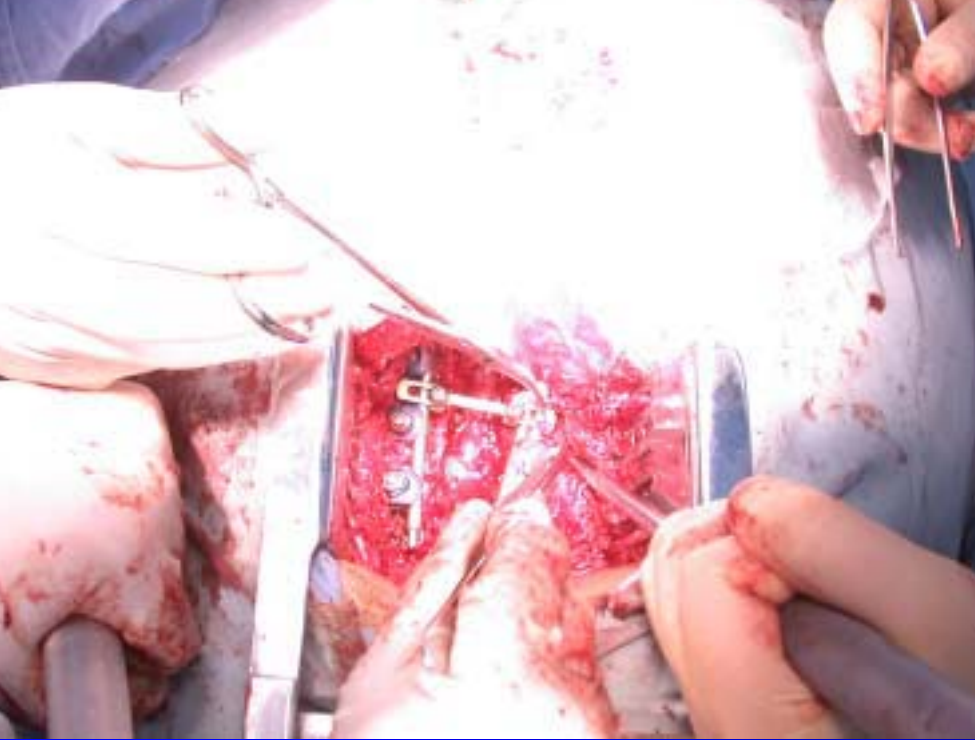




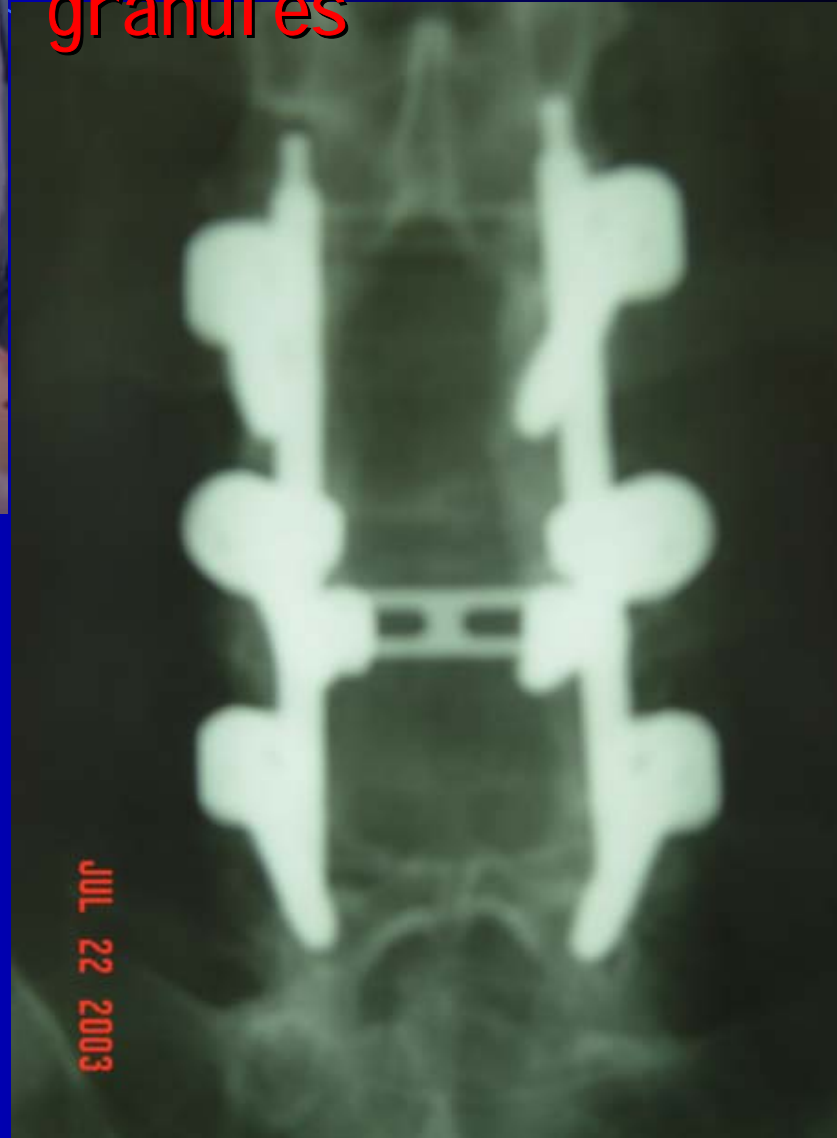
The lateral and anterior-posterior radiograph and computed tomogram of a 55-year-old

woman with degenerated lumbar disc disease, scoliosis, stenosis, lumbar spondylolisthesis at the L4–L5 level, which was refractory to medical care.

Who had definitive neurological damage and was unable to ambulate.



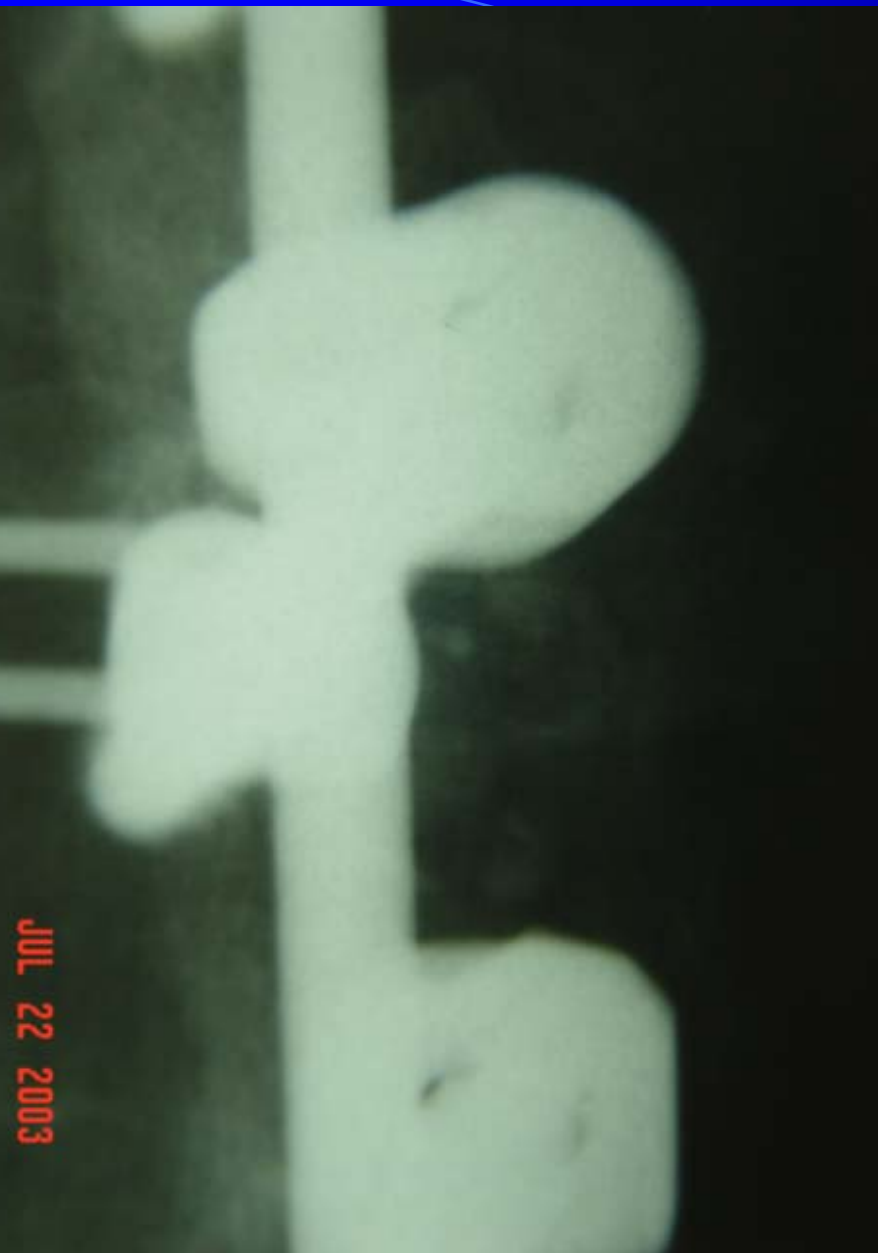Autogenous cancellous bone and Nano-bone granules



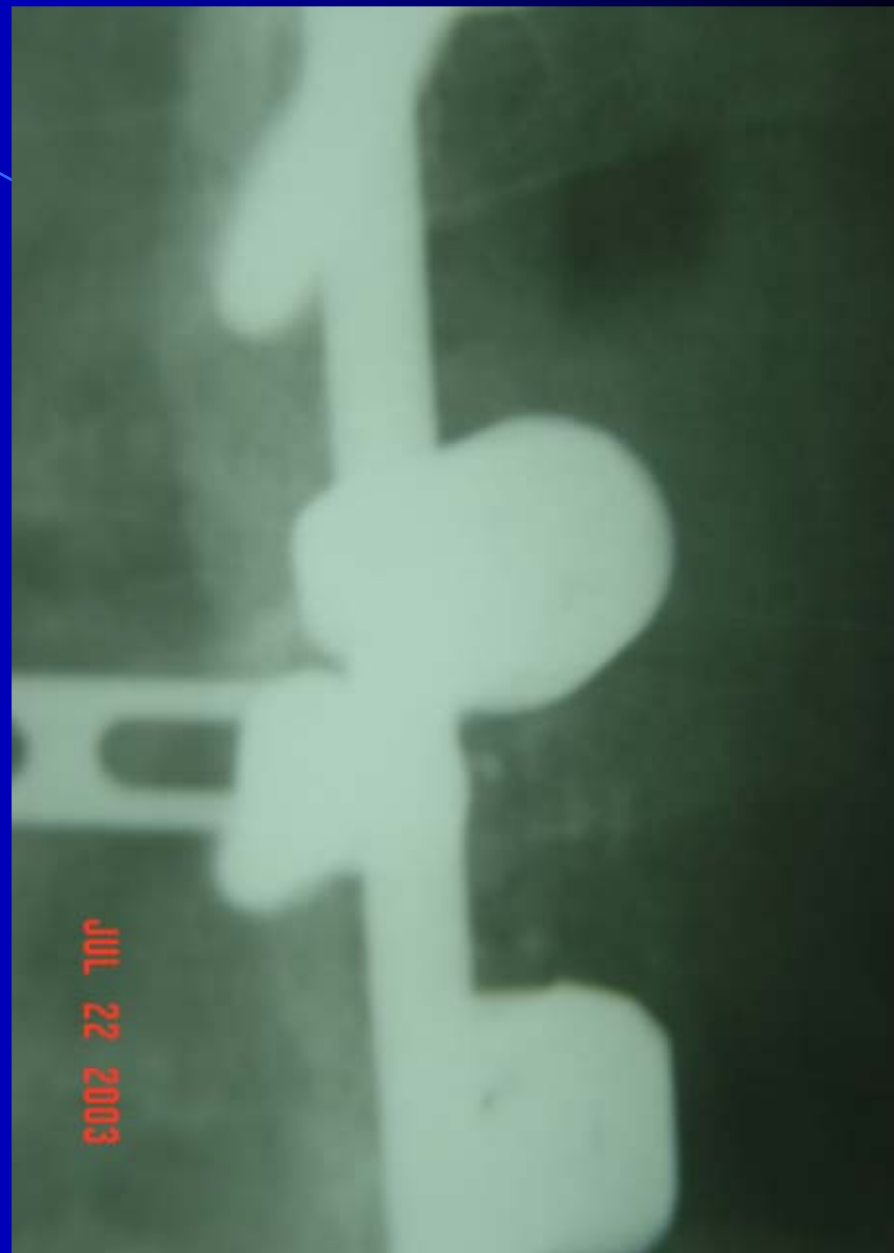JUL 22 2003

Pedicle screw-plate system instrumentation

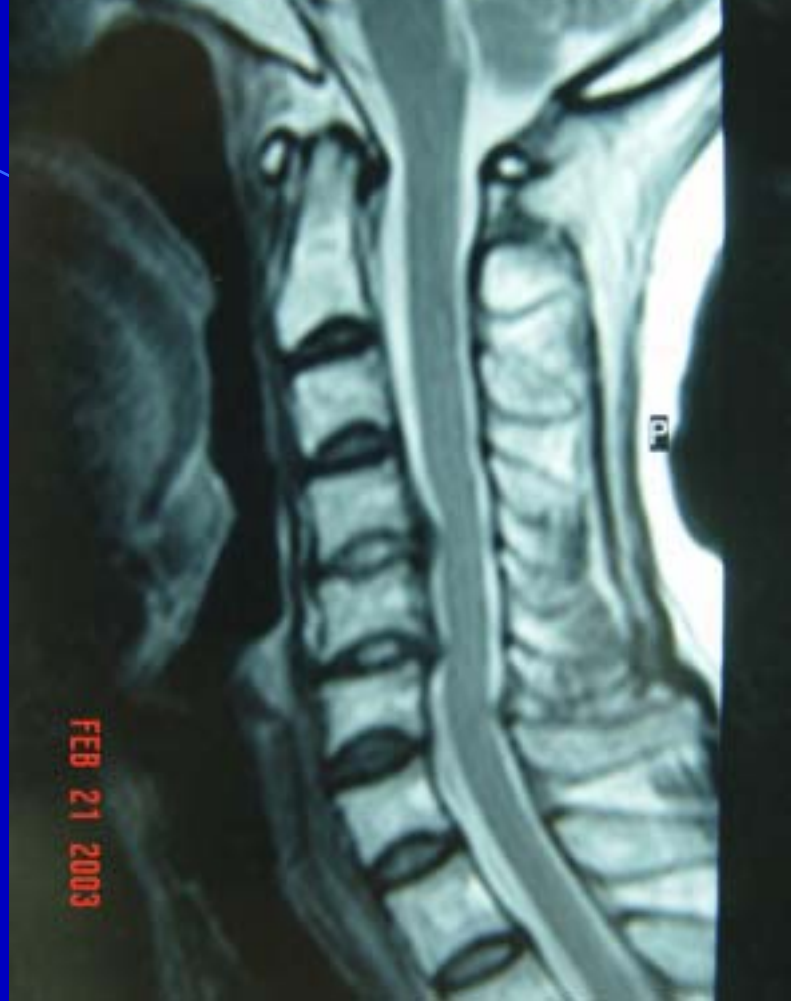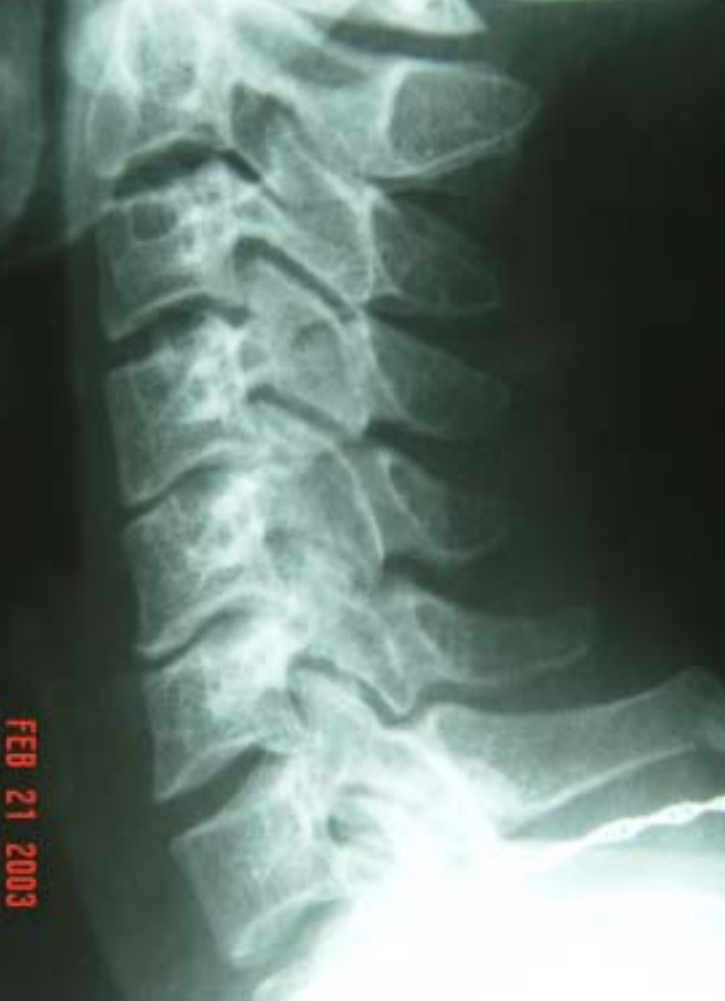Medtronic Sofamor
Danek Tenor System



1 month post-op new bone began to form



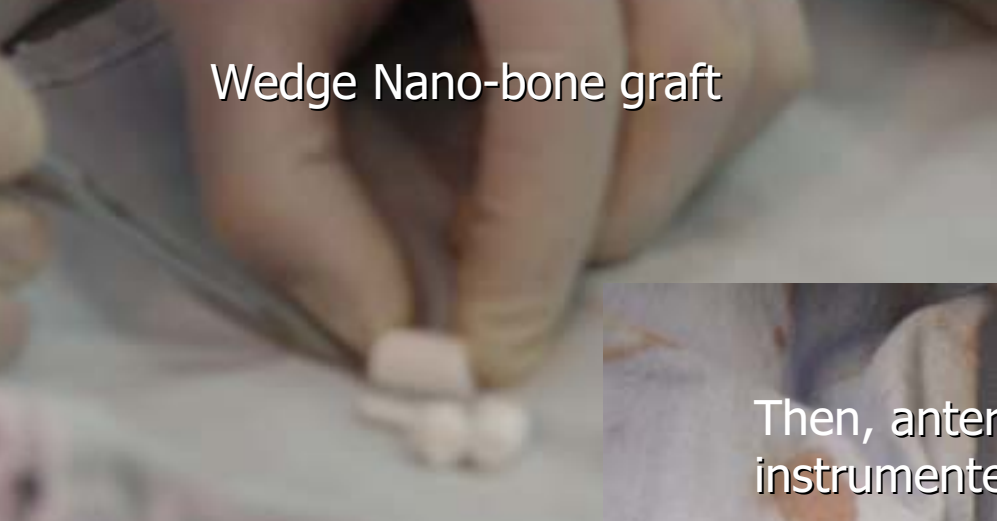4 month post-op bone fusion



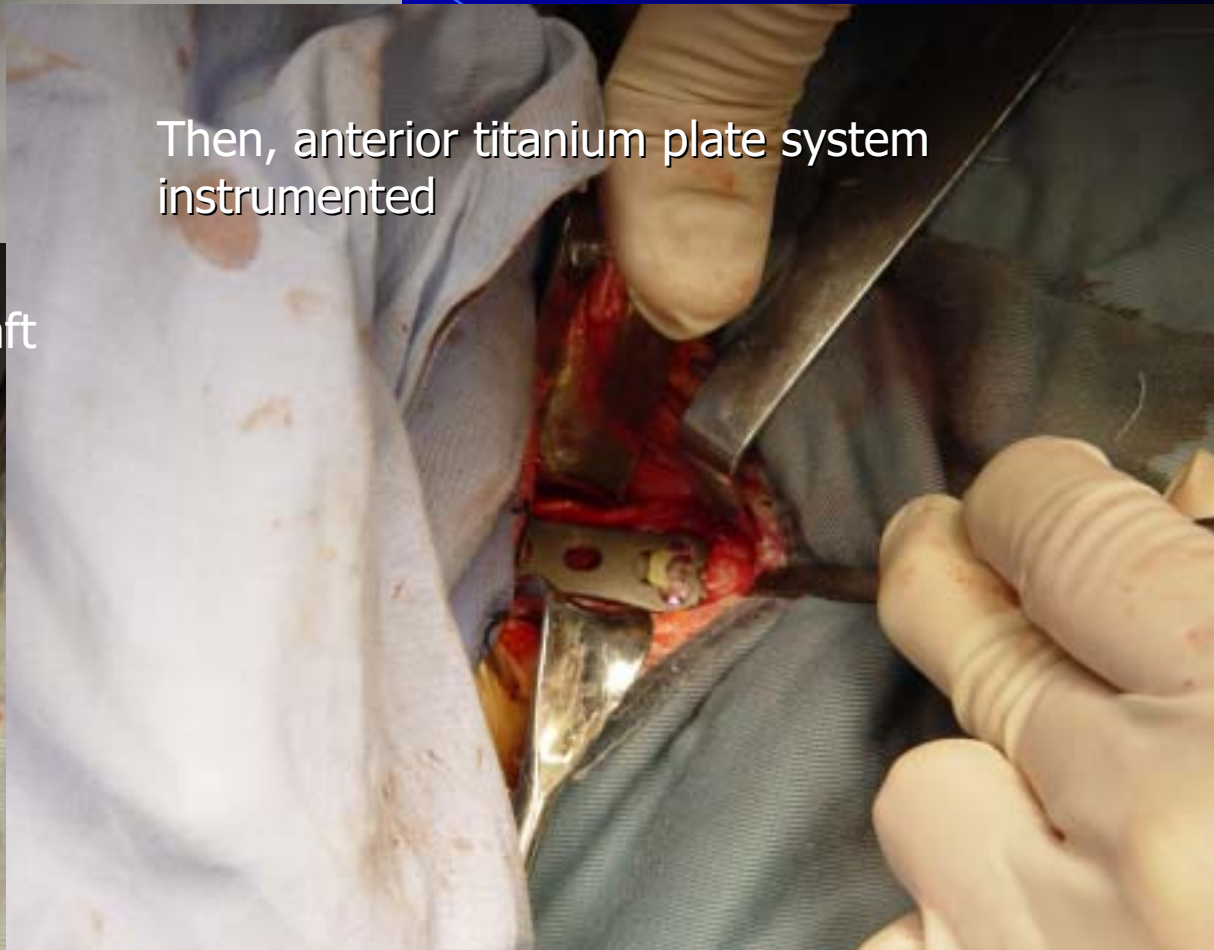Pre-op lateral radiograph and MRI (magnetic resonance image) of a 42-year-old woman with degenerated cervical disc disease at the C4、5 and C5、6 level, ventral intrusion into canal and spinal cord compressed,

Physical exam : myeloradiculopathy associated with incomplete paralysis

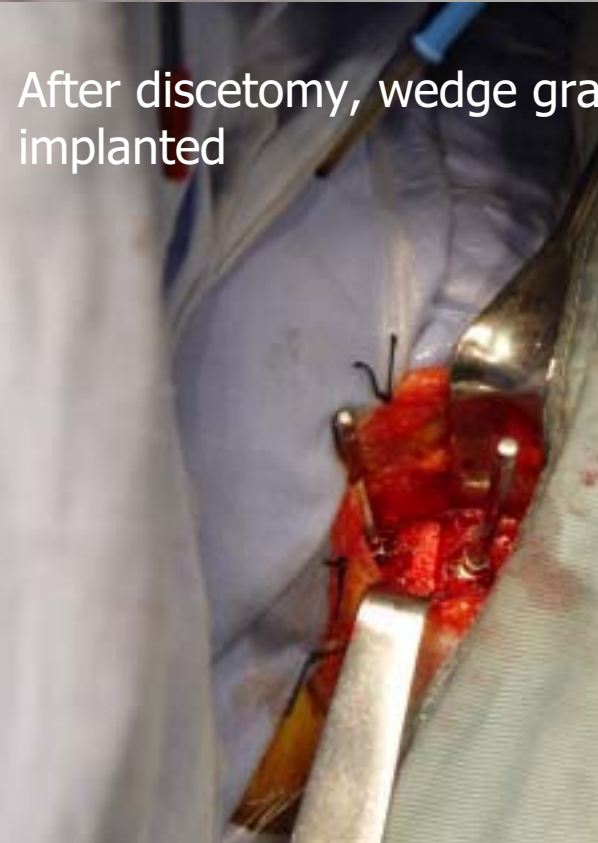
Wedge Nano-bone graft

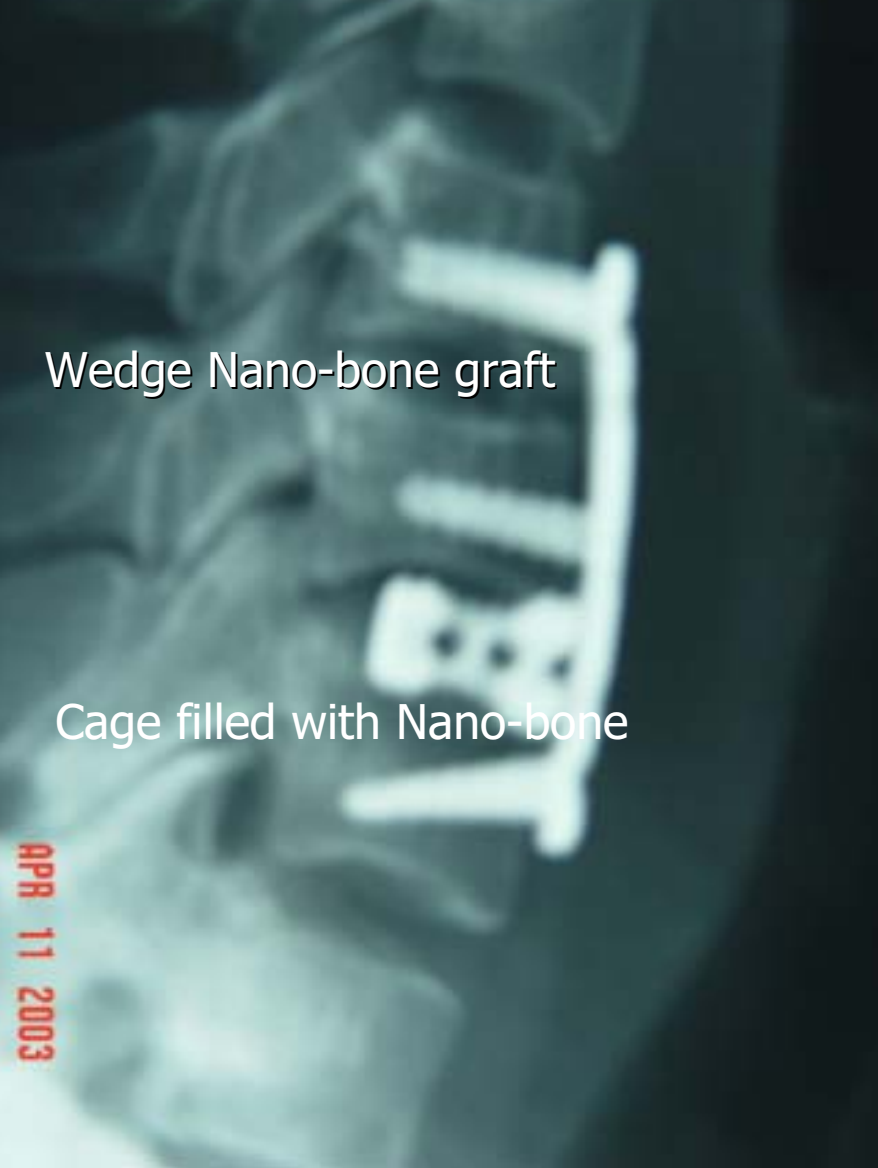


Then, anterior titanium plate system instrumented

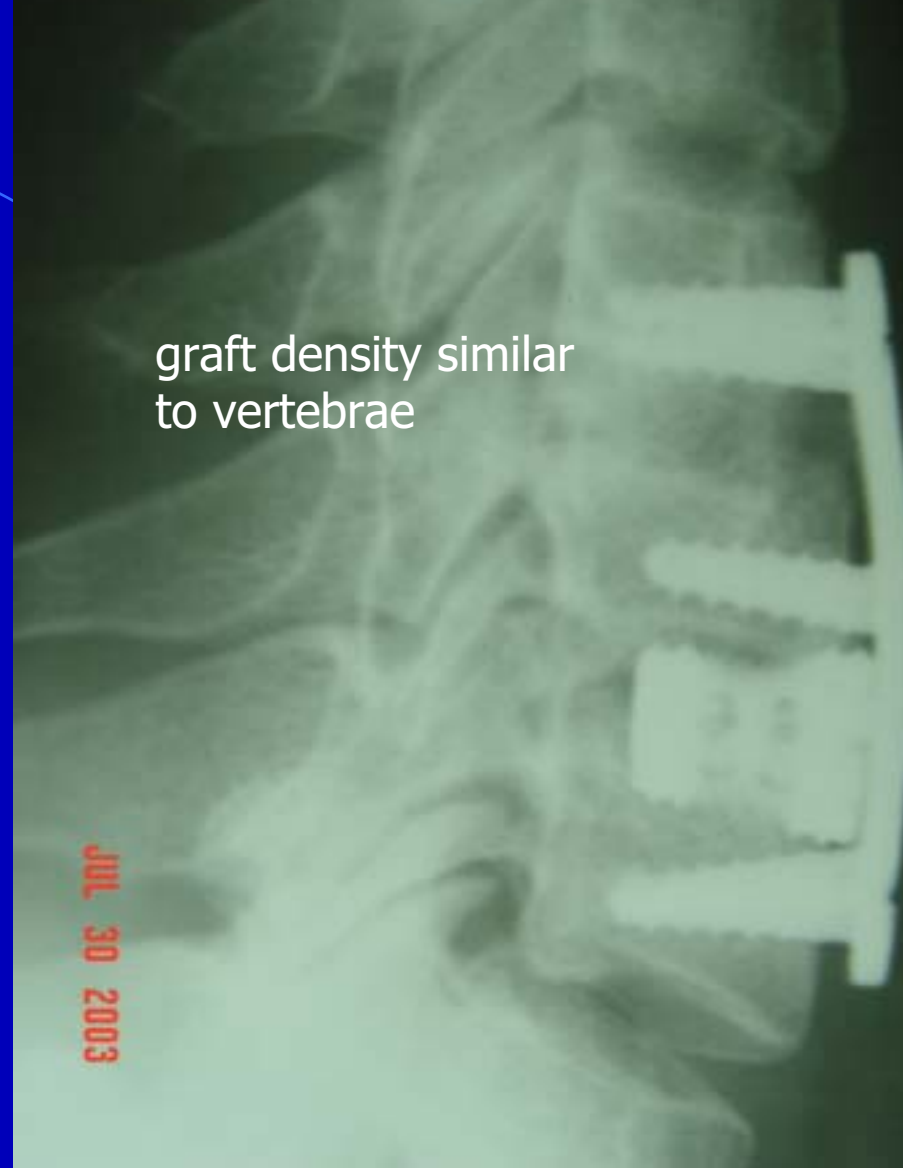


After discectomy, wedge graft implanted



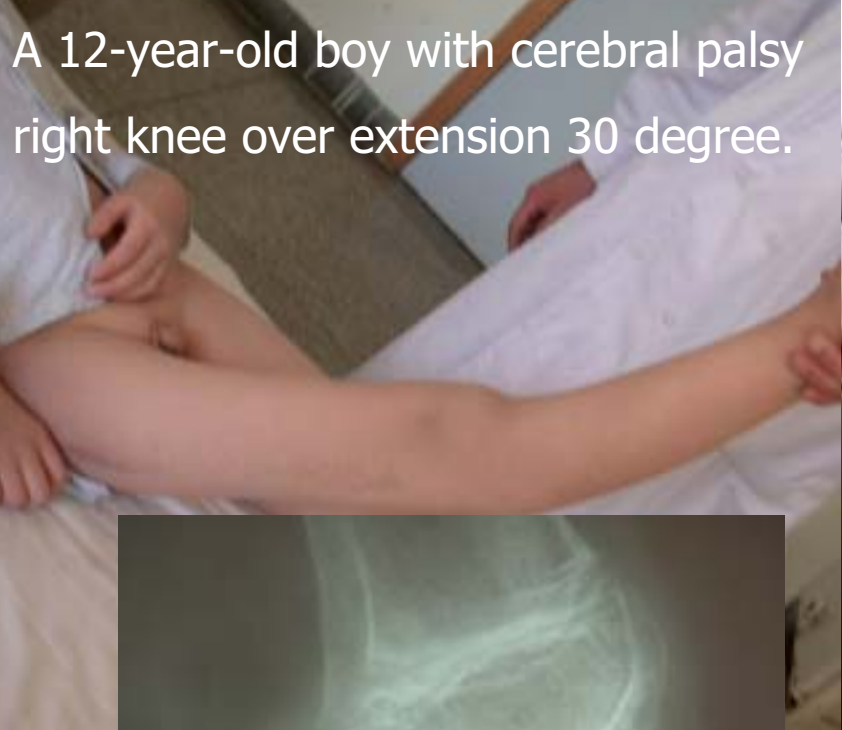

Post-op 2 weeks, low density in radiograph

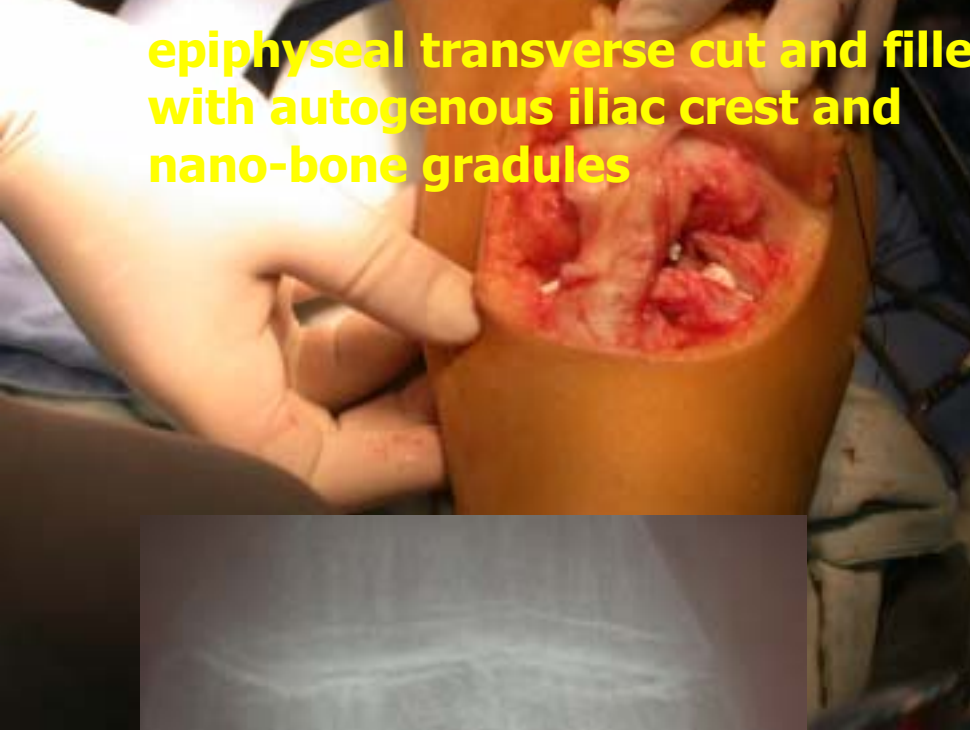

Post-op 3 months, bone fusion

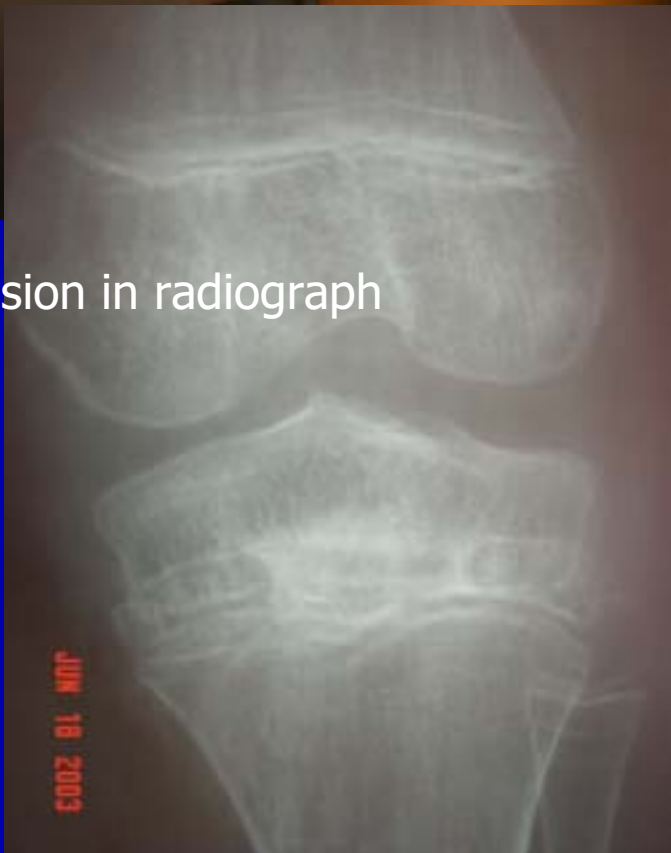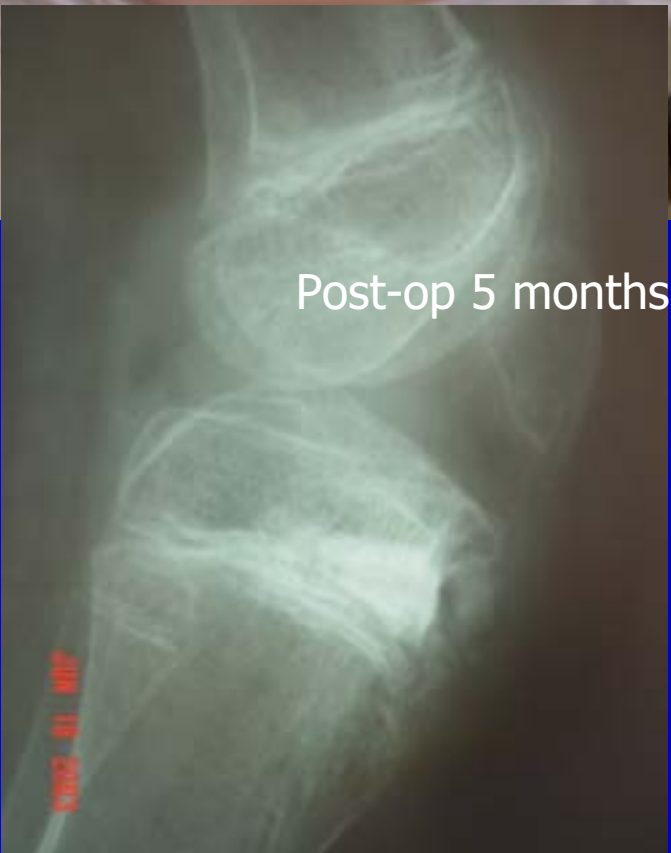A 12-year-old boy with cerebral palsy
right knee over extension 30 degree.



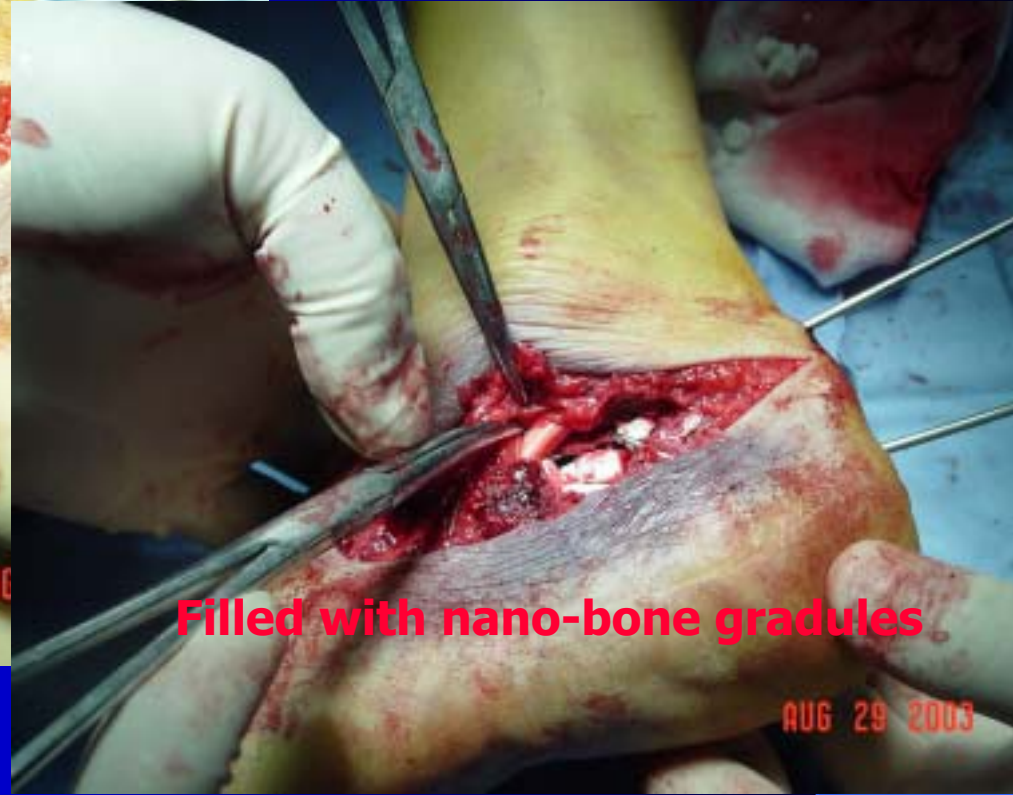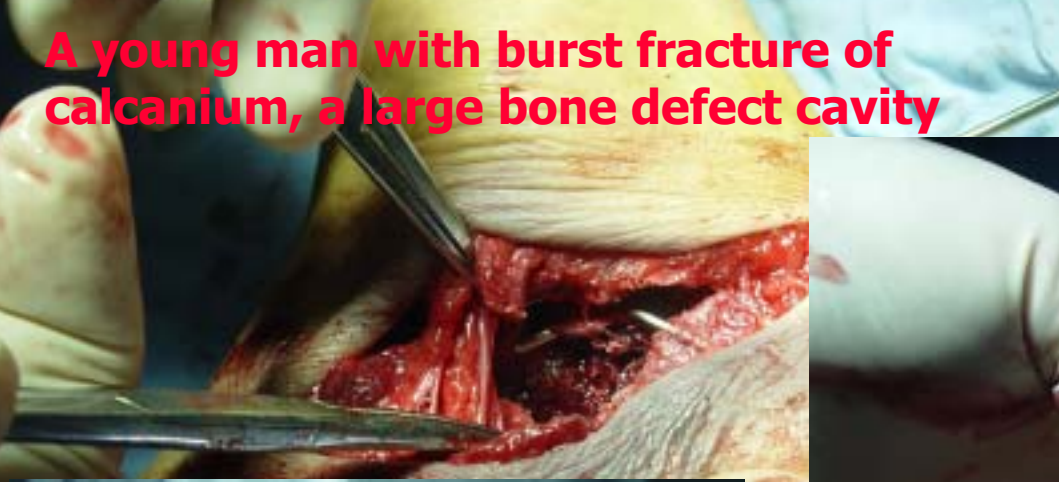
**epiphyseal transverse cut and fille
with autogenous iliac crest and
nano-bone gradules**



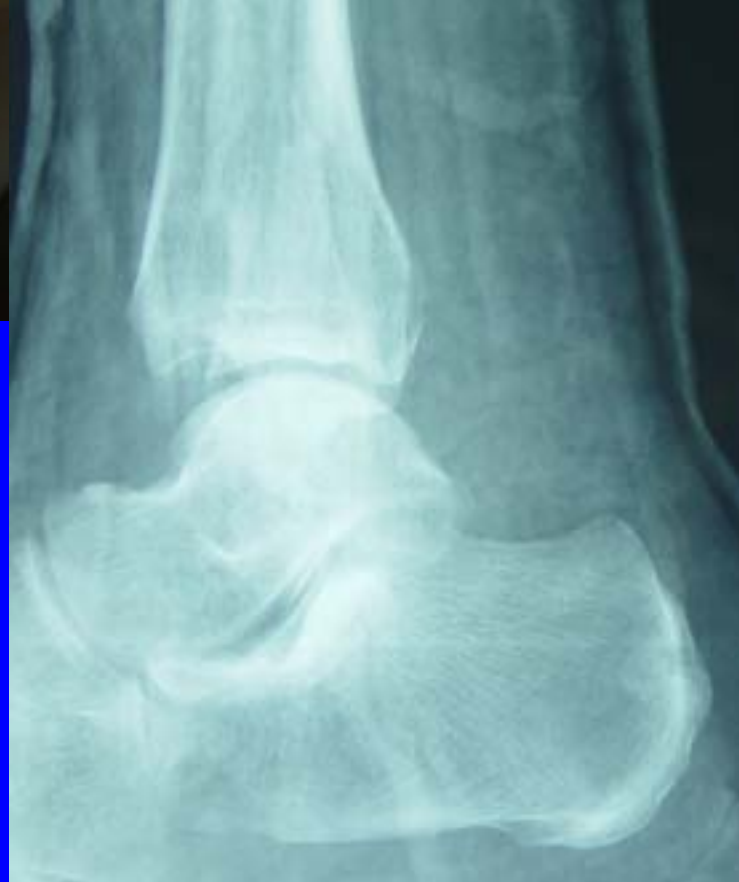Post-op 5 months, bone fusion in radiograph



A young man with burst fracture of calcanium, a large bone defect cavity



Filled with nano-bone granules



Post-op six weeks

conclusion

- Nano-hydroxyapatite/collagen composite has fine histocompatibility, without immunogenic responses from the host.
- The fusion period of nano-bone is about 4-6 months, a litter longer than autograft.
- It may be an relatively ideally alternative substitute to autograft

Hippocratic Oath

You do solemnly swear, each by whatever he or she holds most sacred.

That you will be loyal to the Art of Medicine and just and generous to its members.

That you will leave your patients in no worse condition than you find them in, in business and honor.

That into whatsoever house you shall enter, you shall go in to help the sick to the utmost of your power, your

yourself far aloof from wrong, from corruption, from the temptations of others.

That you will exercise your art solely for the cure of your patients, and will give no operation, for

purpose, even if solicited, far less suggest it.

That whatsoever you shall see or hear of the lives of men or women which is not fitting to be spoken, you will keep in

these things do you swear. Let each bow the head in sign of acquiescence.

And now, if you will be true to this, your oath, may prosperity and good repute be ever yours; the opposite, if you

yourself forsworn.

AUG 21 2003